

# Evaluation of aloe vera gel gloves in the treatment of dry skin associated with occupational exposure

Dennis P. West, PhD<sup>a</sup>

Ya Fen Zhu, MS<sup>b</sup>

Chicago, Illinois, and Jiangsu Province, China

**Objective:** An examination glove that delivers aloe vera (AV) gel to the gloved hand was studied in 30 adult females with bilateral occupational dry skin with or without irritant contact dermatitis (with or without erythema, fissures, and excoriations).

**Methods:** All participants were factory assembly-line workers with repeated superficial skin trauma who attributed their dry, irritated, emollient-dependent skin to a common cause (occupational exposure). Participants were sequentially enrolled (after written informed consent, n = 29 evaluable participants) into an open, contralateral comparison study to evaluate efficacy of AV glove use 8 h/day to one hand versus no use to the opposite hand for 30 days, followed by 30 days rest, followed by 10 days of repeated use. Participant's dorsal hands were documented by standardized photos at baseline, during, and at the end of study.

**Results:** Unblinded investigator baseline assessment rated dry skin as mild to moderate (n = 27), or moderate to severe (n = 2). Mean time to noticeable improvement for the AV glove hand was 3.5 days (range: 2-6 days) whereas marked improvement was 10.4 days (range: 7-17 days) for the AV glove hand. No improvement was detected for nonglove hands.

Blinded photo assessment was rated independently by dermatology research staff. End-of-study mean global assessment of AV glove hands versus nonglove hands was 1.3 for AV glove hand (0 = no change, 1 = good [10%-89% global improvement], 2 = marked improvement [90%-100% global improvement]) versus 0 for nonglove hand ( $P < .0001$ ). Mean global end-of-study assessments by the participants = 2.0 for AV glove hand versus 0 for nonglove hand.

**Conclusion:** Dry-coated AV gloves that provide for gradual delivery of AV gel to skin produced a uniformly positive outcome of improved skin integrity, decreased appearance of fine wrinkling, and decreased erythema in the management of occupational dry skin and irritant contact dermatitis. (*Am J Infect Control* 2003;31:40-2.)

Aloe vera (AV) has been used for centuries in the treatment of human burns and skin wounds.<sup>1</sup> In addition, positive outcomes have been anecdotally reported for decades in selected human cases of leg ulcers, seborrheic dermatitis, acne vulgaris, and

alopecia areata.<sup>1</sup> However, a recent comprehensive literature review (all languages) of clinical trials for AV clinical efficacy, as an oral or topical agent in any clinical condition, yielded only 10 controlled studies.<sup>2</sup> An innovative dry-coating technology has produced a new concept, an examination glove that gradually delivers AV gel to the skin of the gloved hand. In light of almost no substantive controlled clinical research related to AV in the management of dry and irritated skin, we conducted a controlled study to evaluate AV gloves in the management of dry skin associated with occupational exposure.

## METHODS

### Glove preparation

Pure freeze-dried AV was dissolved in distilled water to prepare a 25% AV gel/solution. The AV gel/solution was then applied to the inner surface of the glove and dried through a controlled evaporative

From the Department of Dermatology, Northwestern University, The Feinberg School of Medicine, Chicago,<sup>a</sup> and Shen Wei Zhangjiagang Dayu Rubber Products, Jiangsu Province.<sup>b</sup>

Conflict of interest: At the time of this study, Dennis P. West, PhD, was a consultant to Medline Industries Inc, the distributor of Aloetouch gloves, and Ya Fen Zhu was an employee of a company partially owned by the manufacturer of the Aloetouch gloves.

Reprint requests: Dennis P. West, PhD, Department of Dermatology, Northwestern University, The Feinberg School of Medicine, 675 N St Clair St, Suite 19-200, Chicago, IL 60611-2923.

Copyright © 2003 by the Association for Professionals in Infection Control and Epidemiology, Inc.

0196-6553/2003/\$30.00 + 0

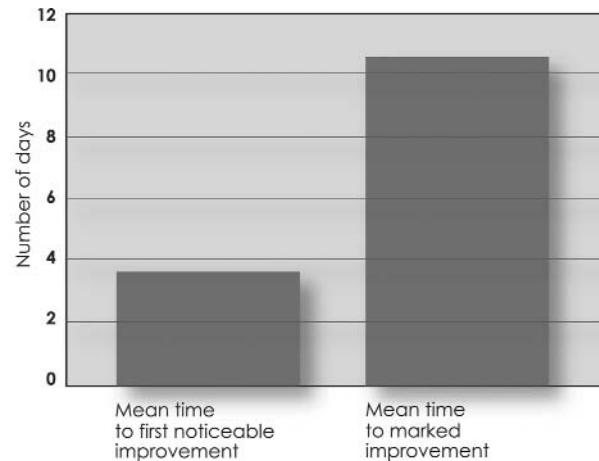
doi:10.1067/mic.2003.12

heating/dehydration process. This water-free, dried AV remained bound to the powder-free, natural rubber latex glove until contact with moisture in the skin of the hand. Upon rehydration by contact with skin moisture, the AV reverted back to a gel/solution that covered the hand to provide a therapeutic response.

The gloves (Aloetouch, Medline Industries Inc, Mundelein, Ill) meet or exceed the ASTM (American Society for Testing and Materials) D3578-00a rubber examination glove standard, ASTM F1671, for viral penetration, and contain less than 50  $\mu\text{g}$  of water-extractable protein per gram.

### Clinical study

Powder-free latex examination gloves with AV were manufactured and then tested in women in a Chinese factory with currently active, clinically dry skin (scaling and with or without erythema) associated with occupational exposure. Some participants had evidence of irritant contact dermatitis (scaling and with or without erythema, fissures, and excoriations) associated with their occupational dry skin. All participants were assembly-line workers with occupationally related xerosis who required maintenance dry-skin care or had irritant contact dermatitis as a result of occupational exposure. Written informed consent was obtained from each participant before any study procedures. The evaluation of photos and data were also approved by the Northwestern University institutional review board. Participants were age selected such that there were 10 participants each in age ranges 25 to 35 years, 36 to 45 years, and 46 years or older. Other than oral contraceptives, no participants were ingesting or applying any medications during the study. A total of 30 adult females with bilateral occupational hand xerosis (clinically dry skin with scaling and with or without erythema; or irritant contact dermatitis with scaling and with or without erythema, fissures, and excoriations) that required daily emollients, all working in the same institution, were sequentially enrolled (after written informed consent,  $n = 29$  evaluable participants) into an open, contralateral comparison study to evaluate the efficacy of repeated AV glove to one hand versus no glove to the contralateral hand during 30 days, followed by 30 days rest, followed by 10 days of repeated study. The participants' dorsal hands were documented by standardized photography at baseline, during, and at the end of study. To optimize interrater reliability, blinded photographic assessment was rated indepen-



**Fig.** Onset of skin-quality improvement with AV glove use.

dently by 2 dermatology clinical research staff members at Northwestern University who routinely do skin patch testing and photographic assessments in dermatology. Independent scores from each assessor were averaged for purposes of the study. The blinded paired means were evaluated statistically with the Wilcoxon signed rank test.

### RESULTS

Baseline unblinded investigator assessment rated the level of dry skin as mild to moderate (minimal scaling with minimal evidence of erythema and excoriation) ( $n = 27$ ), or moderate to severe (obvious scaling with obvious erythema, fissures, and excoriations) ( $n = 2$ ). Mean time to first noticeable improvement in skin quality for the AV glove hand was 3.5 days (range: 2–6 days). Mean time to marked improvement in skin quality was 10.4 days (range: 7–17 days) for the AV glove hand. There was no improvement (ie, noticeable improvement or marked improvement) for nonglove hands in any participant (Fig).

Blinded photographic assessment was rated independently by 2 dermatology clinical research staff members at Northwestern University who routinely do skin patch testing and assessment scoring. The independent scores from each assessor were averaged. Blinded, end-of-study global photographic assessment of AV glove versus nonglove hands rated improvement at a mean of 1.3 for the AV glove hands (0 = no change, 1 = good [10%–89% global improvement], 2 = marked improvement [90%–

100% global improvement]) versus 0 for the non-glove hands ( $P < .0001$ ).

Mean global end-of-study assessments by the participants were 2.0 for the AV glove hands versus 0 for the nonglove hands. Allergic contact dermatitis for any reason was not observed during the course of this study.

## DISCUSSION

The basis for the clinically beneficial properties of AV is found in numerous animal studies that point to some of the possible mechanisms of action in the therapeutic use of topical AV to manage various dermatoses, including irritant contact dermatitis and dry skin.

Modified aloe polysaccharide (the most biologically active components of aloe) activates macrophages and stimulates fibroblasts.<sup>3</sup> Support for these effects is substantiated by demonstrating prevention of UV-B irradiation-induced immune suppression as determined by contact hypersensitivity response and inhibition of UV-B-induced tumor necrosis factor- $\alpha$  release.<sup>3</sup> This also indicates that aloe may decrease the risk of sun-related skin cancer.

AV has been demonstrated to inhibit inflammation and to promote wound healing.<sup>4</sup> In mice, both oral and topical AV has been shown to be effective in wound healing.<sup>5</sup> One of the possible active ingredients of AV is mannose-6-phosphate, shown to be anti-inflammatory and to promote wound healing in mice.<sup>6</sup> More recently, a glycoprotein fraction present in AV with a molecular weight of 5.5 kDa has been identified and shown to be effective for wound healing in a hairless mouse model.<sup>7</sup>

Moreover, an excisional wound model in rats demonstrated promotion of wound healing by AV in the presence of mafenide acetate, a compound that is known to inhibit wound healing.<sup>8</sup>

Tissue healing is accomplished primarily by production of collagen in the revised extracellular matrix. In rat dermal wounds, AV increased the type III collagen content of new granulation tissue under controlled conditions.<sup>9</sup> Further, topical AV has been found to promote the synthesis of glycosaminoglycans, the ground substance component of the matrix that precedes the development of granulation tissue in the early stages of a healing wound.<sup>10</sup>

AV properties are reported to include its ability to transit skin; anesthetize skin; inhibit growth of bacteria, fungi, and viruses; inhibit inflammation; and dilate vessels with subsequent enhancement of cutaneous blood flow.<sup>11</sup>

## CONCLUSION

The scientific basis for using topical AV to irritated, dry skin is well reported, but controlled studies have been rarely reported. Our study has substantiated that those who have, or are at risk of having, irritant contact dermatitis, particularly occupation-related, show a marked improvement in their skin quality with the use of AV gel gloves. Of note, all study participants exhibited significant skin improvement and no participants demonstrated any adverse reactions. The advanced technology of dry-coating gloves with AV provides for prolonged and continual delivery of AV gel to the skin with a uniformly positive outcome of improved skin integrity, decreased appearance of fine wrinkling, and decreased erythema.

## References

1. El Zawahry M, Hegazy MR, Helal M. Use of aloe in treating leg ulcers and dermatoses. *Int J Dermatol* 1973;12:68-73.
2. Vogler BK, Ernst E. Aloe vera: a systematic review of its clinical effectiveness. *Br J Gen Pract* 1999;49:823-8.
3. Qiu Z, Jones K, Wylie M, Jia Q, Orndorff S. Modified aloe barbadensis polysaccharide with immunoregulatory activity. *Planta Med* 2000;66:152-6.
4. Davis RH, Rosenthal KY, Cesario LR, Rouw GA. Processed aloe vera administered topically inhibits inflammation. *J Am Podiatr Med Assoc* 1989;79:395-7.
5. Davis RH, Leitner MG, Russo JM, Byrne ME. Wound healing—oral and topical activity of aloe vera. *J Am Podiatr Med Assoc* 1989;79:559-62.
6. Davis RH, DiDonato JJ, Hartman GM, Haas RC. Anti-inflammatory and wound healing activity of a growth substance in aloe vera. *J Am Podiatr Med Assoc* 1994;84:77-81.
7. Choi S-W, Son B-W, Son Y-S, Park Y-I, Lee S-K, Chung M-H. The wound-healing effect of a glycoprotein fraction isolated from aloe vera. *Br J Dermatol* 2001;145:535-45.
8. Heggors JP, Kucukcelebi A, Listengarten D, Stabeneau J, Ko F, Broemeling LD, et al. Beneficial effect of aloe on wound healing in an excisional wound model. *J Altern Complement Med* 1996;2:271-7.
9. Chithra P, Sajithlal GB, Chandrakasan G. Influence of aloe vera on collagen characteristics in healing dermal wounds in rats. *Mol Cell Biochem* 1998;181:71.
10. Chithra P, Sajithlal GB, Chandrakasan G. Influence of aloe vera on the glycosaminoglycans in the matrix of healing dermal wounds in rats. *J Ethnopharmacol* 1998;59:179-86.
11. Heggors JP, Kucukcelebi A, Stabeneau CJ, Ko F, Broemeling LD, Robson MC, et al. Wound healing effects of aloe gel and other topical antibacterial agents on rat skin. *J Phytother Res* 1994;9:455-7.